

Case 6

Dr. Namazi (Ped. Rheumatologist)

-
- **A 10 y/o boy (wt: 41 kg) with good general condition, came to our clinic with limping from 7 months ago.**

History

- **PMH : Neg**
- **FH : His father has been taking sulfasalazine tab& NSAIDs for several years due to chronic back pain .**
- **D.H : Only NSAIDs (PRN)**

Review of systems

- **What questions do you ask the patient ?**

- **Pain characterization** ? Increase with rest , morning stiffness , gelling pain
- **Previous infections** ? No
- **Fever or systemic symptoms?** No
- **Rash or Coagulopathies** ? No
- **Trauma** ? No
- **B-Symptoms or close contact to tuberculosis** ? No
- **History of consuming unpasteurized dairy products** ? No

PH.EX

- **Gait : Antalgic gait**
- **Hope on one foot**
- **Walk on heels & toes**
- **Squatting**
- **Evaluate the shoes**

Common cause of antalgic gait

- **Trauma**
- **SCFE**
- **Inflammation**
- **Tumors**

PH.EX (continued...)

Local examination

- Skin
- Muscle
- Joints : Pain & LOM in Rt Hip (Int . rotation)
- Bones
- Vascular

PH.EX (continued...)

- **Special maneuvers**

FABER test on Rt hip is positive !

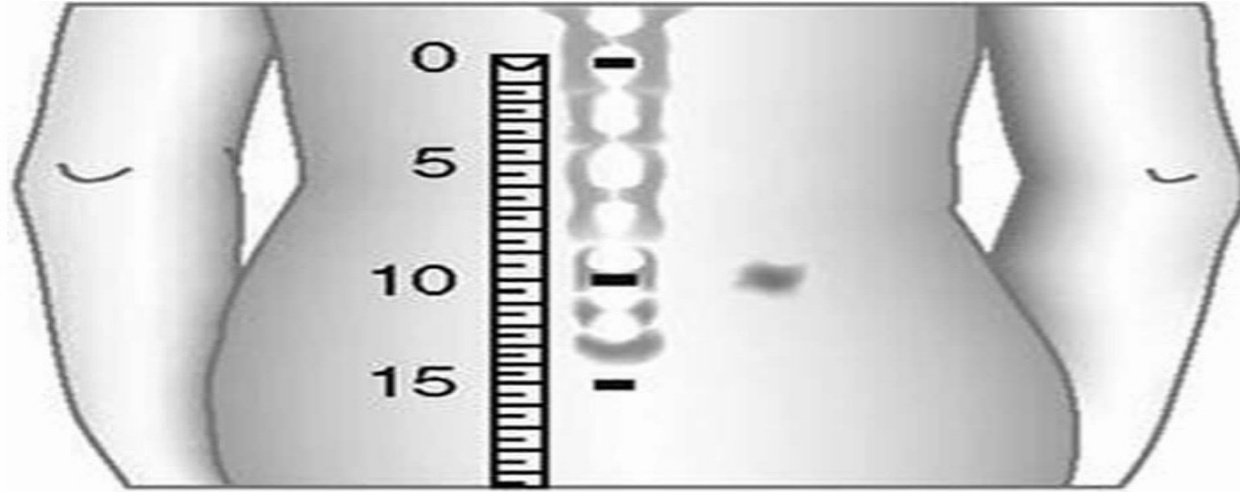
- **Distant examination**

Bilateral tenderness on sites of insertion of the Achilles tendon into the calcaneus

No sacroileitis !

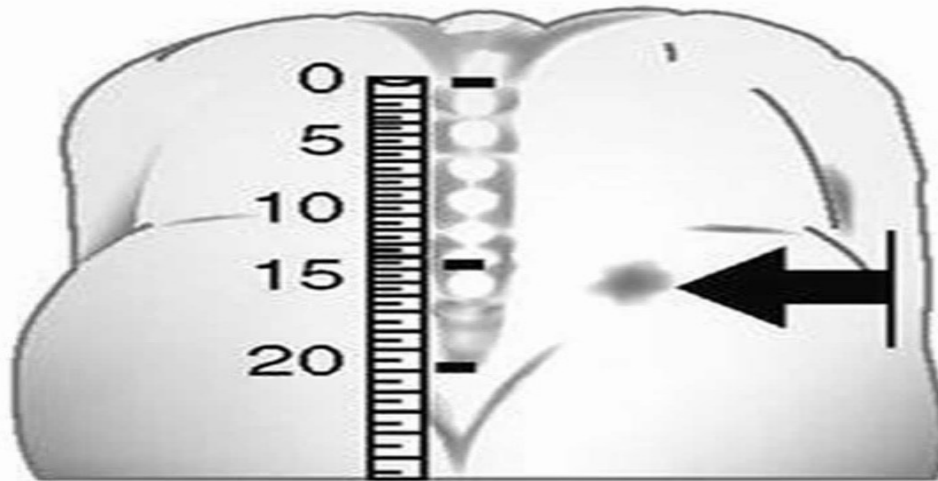
PATRICK TEST (FABER)





Modified
Schober's

15-cm segment
should
expand to
greater than
21 cm when
flexed forward



Dimple
of Venus

-
- **Don` t forget spinal , abdominal or pelvic pathologies ...**

Lab data

- **CBC diff & CRP : NI**
- **ESR : 45 - 52 mm/h**
- **ANA & RF : Neg**
- **Wright , Coombs wright , 2ME : Neg**
- **PPD : Neg**



X-ray indication?



? **Do you admit this patient**



DDX ?

Inflammatory chronic monoarthritis

- **JIA**s

- oJIA

- **SpAs**

- ReA

- IBD

- JP_sA

- JAS (ERA)

- **Infections**

Brucellosis

Joint tuberculosis

- **CTD**

SLE & JDM & JPM

- **Vasculopathies**

HSP & Kawasaki & PAN & Behcet ...

- **Autoinflammatory disorders**

sJIA & FMF

More W/u

**Hip sonography :Mild effusion on Rt hip +
synovial hypertrophy (on the same hip)**

Arthrocentesis result : WBc : 5500 (PMN : 55%)

Synovial Rt-hip biopsy : Neg for TB

HLA-B27 : Positive

Pelvic MRI : Non specific inflammatory changes

- **10 y/o Boy**

+

- **FH positive of inflammatory back pain**

+

- **Chronic inflammatory Rt hip arthritis**

+

- **Enthesitis**

+

- **HLA-B27+**

D_x : JAS (ERA)

Thank you !

